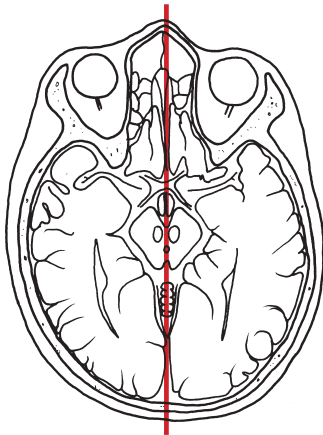
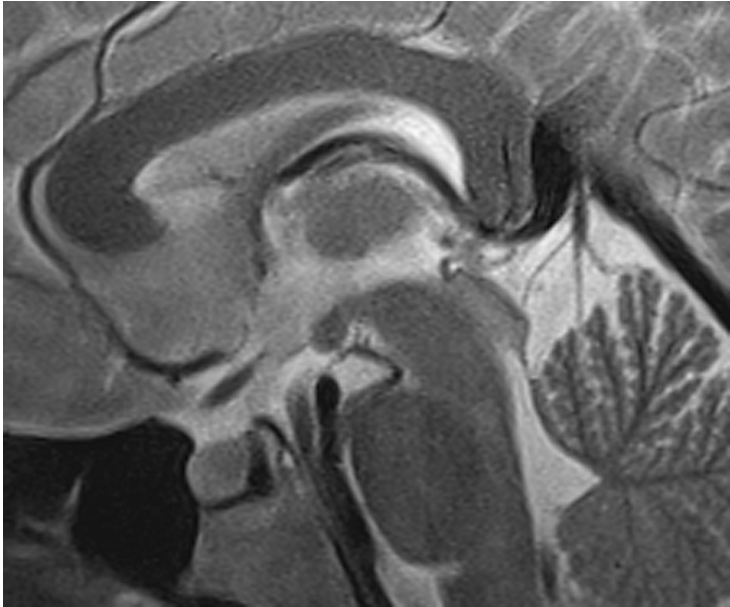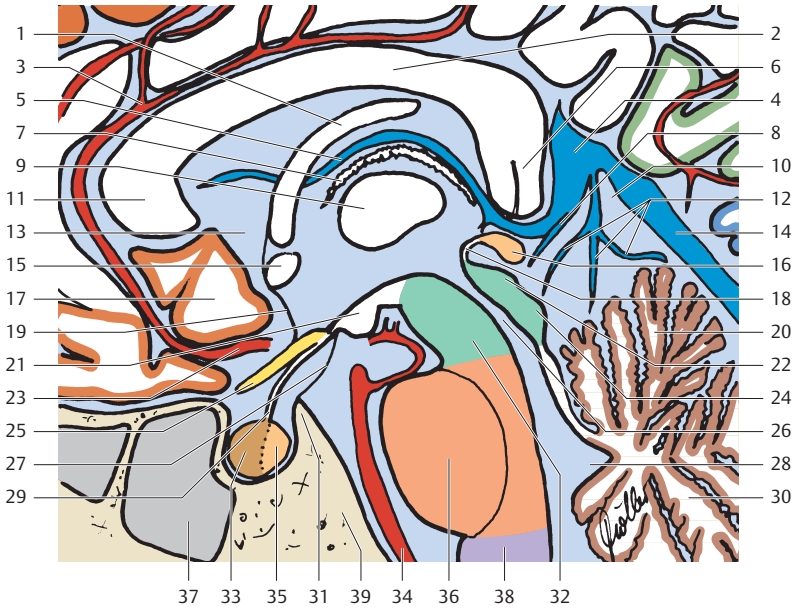


-  Frontallappen
-  Parietallappen
-  Okzipitallappen
-  Zerebellum
-  Mesenzephalon
-  Pons
-  Medulla oblongata



- | | |
|--|--|
| 1 Fornix (Corpus) | 23 A. cerebri anterior |
| 2 Corpus callosum (Truncus) | 24 Lamina tectalis [quadrigemina]
(Vierhügelplatte, Colliculus posterior) |
| 3 A. pericallosa | 25 N. opticus (II) |
| 4 V. cerebri magna | 26 Aquädukt |
| 5 V. cerebri interna | 27 Lilliequist-Membran |
| 6 Corpus callosum (Splenum) | 28 IV. Ventrikel (Dach) |
| 7 Plexus choroideus | 29 Infundibulum (Hypophysenstiel) |
| 8 V. basalis (Rosenthal) | 30 Kleinhirnhemisphäre
(Lobulus caudalis [posterior]) |
| 9 Adhaesio interthalamica | 31 Dorsum sellae |
| 10 Cisterna venae cerebri magnae | 32 Mesencephalon |
| 11 Corpus callosum (Genu) | 33 Hypophysenvorderlappen
(Adenohypophyse) |
| 12 Vv. cerebelli | 34 A. basilaris |
| 13 III. Ventrikel | 35 Hypophysenhinterlappen
(Neurohypophyse) |
| 14 Sinus rectus | 36 Pons |
| 15 Commissura anterior | 37 Sinus sphenoidalis |
| 16 Corpus pineale | 38 Medulla oblongata |
| 17 Gyrus praeterterminalis | 39 Clivus |
| 18 Commissura posterior | |
| 19 Lamina terminalis | |
| 20 Kleinhirnhemisphäre (Lobulus
caudalis [anterior]) | |
| 21 Corpus mamillare | |
| 22 Lamina tectalis [quadrigemina]
(Vierhügelplatte, Colliculus
superior) | |